

BRIEF COMMUNICATION

Subtle retinal pathology in amyotrophic lateral sclerosis

Marius Ringelstein^{1,a}, Philipp Albrecht^{1,a}, Martin Südmeyer^{1,2}, Jens Harmel¹, Ann-Kristin Müller¹, Nazmiye Keser¹, David Finis³, Stefano Ferrea^{1,2}, Rainer Guthoff³, Alfons Schnitzler^{1,2}, Hans-Peter Hartung¹, Axel Methner^{1,4,a} & Orhan Aktas^{1,a}

¹Department of Neurology, Medical Faculty, Heinrich-Heine University, Düsseldorf, Germany

²Institute of Clinical Neuroscience and Medical Psychology, Medical Faculty, Heinrich-Heine University, Düsseldorf, Germany

³Department of Ophthalmology, Medical Faculty, Heinrich-Heine University, Düsseldorf, Germany

⁴Department of Neurology, Medical Faculty, Johannes Gutenberg University, Mainz, Germany

Correspondence

Orhan Aktas, Department of Neurology, Heinrich-Heine University, Medical Faculty, Moorenstraße 5, 40225 Düsseldorf, Germany. Tel: +49 211/81 18464; Fax: +49 211/81 18469; E-mail: orhan.aktas@uni-duesseldorf.de

Funding Information

We thank the Walter and Ilse Rose Stiftung, the "Helmholtz Alliance for Mental Health in an Ageing Society" (HelMA, HA-215) and the "Helmholtz Impuls- und Vernetzungsfonds" funded by the German "Bundesministerium für Bildung und Forschung" (BMBF) for support.

Received: 6 January 2014; Revised: 29 January 2014; Accepted: 2 February 2014

Annals of Clinical and Translational Neurology 2014; 1(4): 290–297

doi: 10.1002/acn3.46

^aThese authors contributed equally.

Introduction

Amyotrophic lateral sclerosis (ALS) is characterized by upper and lower motor neuronal degeneration, resulting in progressive weakness of the limbs as well as the respiratory and bulbar musculature.^{1,2} Remarkably, autopsy studies such as recent investigations on phosphorylated 43 kDa TAR DNA-binding protein (pTDP-43) distribution have shown alterations beyond the pyramidal tract, including the neo- and allocortex, and the basal ganglia.³ Extra-motor symptoms occur more frequently than previously thought and comprise neuro-ophthalmological abnormalities such as decreased high and low contrast visual acuity.^{4,5} In line with this evidence, studies on visual evoked potentials⁶ and voxel-based MRI volumetry

Abstract

Amyotrophic lateral sclerosis (ALS) is characterized by neuro-ophthalmological abnormalities beyond disturbed oculomotor control such as decreased visual acuity and disturbed visual evoked potentials. Here we report retinal alterations in a cohort of 24 patients with clinically definite ($n = 20$) or probable ($n = 4$) ALS as compared to matched controls. High-resolution spectral domain optical coherence tomography with retinal segmentation revealed a subtle reduction in the macular thickness and the retinal nerve fiber layer (RNFL) as well as a marked thinning of the inner nuclear layer (INL). Our data indicate an unprecedented retinal damage pattern and suggest neurodegeneration beyond the motor system in this disease.

of the occipital cortex revealed functional and structural alterations of the visual system in ALS.⁷

Spectral domain optical coherence tomography (SD-OCT) is a noninvasive technique utilizing near-infrared light to generate cross-sectional images of the retina as part of the central nervous system (CNS).⁸ SD-OCT allows quantitative imaging of the retinal nerve fiber layer (RNFL), representing the innermost layer with the unmyelinated axons of the retinal ganglion cells. Moreover, in-depth analysis of the perifoveal segment is possible, allowing segmentation of the different retinal layers including the ganglion cell layer (GCL), the inner plexiform layer (IPL), the inner nuclear layer (INL), the outer plexiform layer (OPL), and the outer nuclear layer (ONL).⁸ This technique has been successfully applied in

diseases like multiple sclerosis with retinal alterations even in the absence of optic neuritis^{9–12} as well as in primary neurodegenerative diseases, including parkinsonian syndromes, Wilson's, and Alzheimer's disease.^{13–15}

Following these findings we performed a cross-sectional study to analyze the possible involvement of the retina in ALS. We here report subtle alterations of the RNFL and the total macular thickness as well as a marked reduction in the INL, suggesting neurodegeneration beyond the motor system in this disease.

Methods

Cohorts

Overall, 24 consecutive patients with “clinically definite” ($n = 20$) or “clinically probable” ($n = 4$) ALS diagnosis by the consensus of two experienced neurologists following the Awaji criteria¹⁶ and 24 healthy age- and sex-matched controls were enrolled for this study between September 2010 and September 2012 (Table 1). All patients recruited at our center gave written informed consent and underwent a formal ophthalmologic examination including fundoscopy, tonometry, slit lamp examination, and assessment of best corrected visual acuity.

Patients and controls were comparable for age and gender, with a male preponderance (Table 1). Patients with “clinically possible” ALS,¹⁶ with ophthalmologic abnormalities (history of retinopathy, glaucoma, severe myopia, hyperopia of ± 5 dpt.), and with other inflammatory or degenerative neurological diseases were excluded. The study was approved by the local ethics committee of the Medical Faculty of the Heinrich-Heine University Düsseldorf, Germany (study registry #2849).

SD-OCT

SD-OCT was performed using a Spectralis[®] setup with TruTrack[®] image alignment eye tracking (Heidelberg Engineering, Heidelberg, Germany) for perifoveal volumetric retinal scans (25 single vertical axial scans, scanning area: 6×6 mm, centered at the fovea, Fig. 1A). Peripapillary RNFL was assessed with a 12° circular scan centered on the optic disk (Fig. 1B). RNFL- and paramacular volumetric scans were automatically evaluated by the manufacturer's Eye Explorer[®] package (1.7.1.0; Heidelberg Engineering). The deeper retinal layers (ganglion cell/inner plexiform layer complex [GCIP], INL, OPL, and ONL) were measured by manually positioning segmentation lines on the borders between the different

Table 1. Demographic patient data and optical coherence tomography parameters.

Characteristics	ALS patients ($N = 24$)	Healthy controls ($N = 24$)
Diagnosis – no. (%)		
Clinically definite	20 (83)	n.a.
Clinically probable	4 (17)	n.a.
Age – yr (range)	61.5 ± 13.0 (34–82)	61.6 ± 15 (33–84)
Male sex – no. (%)	19 (79)	17 (71)
Interval disease manifestation to OCT – mo (range)	22.3 ± 22.57 (3–120)	n.a.
Riluzole treatment at OCT – no. (%)	7 (29)	n.a.
Duration of riluzole treatment before OCT – mo (range)	17 (1–55)	n.a.
OCT parameters		
Mean RNFL – μm	93.23 ± 10.67	99.98 ± 10.89
Mean GCIP – μm	66.15 ± 6.57	66.47 ± 6.62
Mean INL – μm	24.72 ± 3.22	27.87 ± 4.34
Mean OPL – μm	29.50 ± 3.58	30.89 ± 4.47
Mean ONL – μm	61.57 ± 7.53	60.50 ± 7.82
P.E. GCIP – μm	97.13 ± 8.83	99.98 ± 9.21
P.E. INL – μm	37.42 ± 4.64	43.29 ± 4.22
P.E. OPL – μm	41.25 ± 5.98	35.52 ± 7.00
P.E. ONL – μm	107.67 ± 10.61	105.91 ± 12.68
MT – μm	309.83 ± 17.29	318.24 ± 15.65

Table 1 Indicated are the demographic data and the mean retinal layer thicknesses and standard deviations for the acquired parameters of ALS patients and healthy controls. The abbreviations are as follows: ALS, amyotrophic lateral sclerosis; GCIP, ganglion cell/inner plexiform layer complex; INL, inner nuclear layer; Mean, mean layer thickness; MT, macular thickness; n.a., not applicable; OCT, optical coherence tomography; ONL, outer nuclear layer; OPL, outer plexiform layer; P.E., point estimate measurement; RNFL, retinal nerve fiber layer.

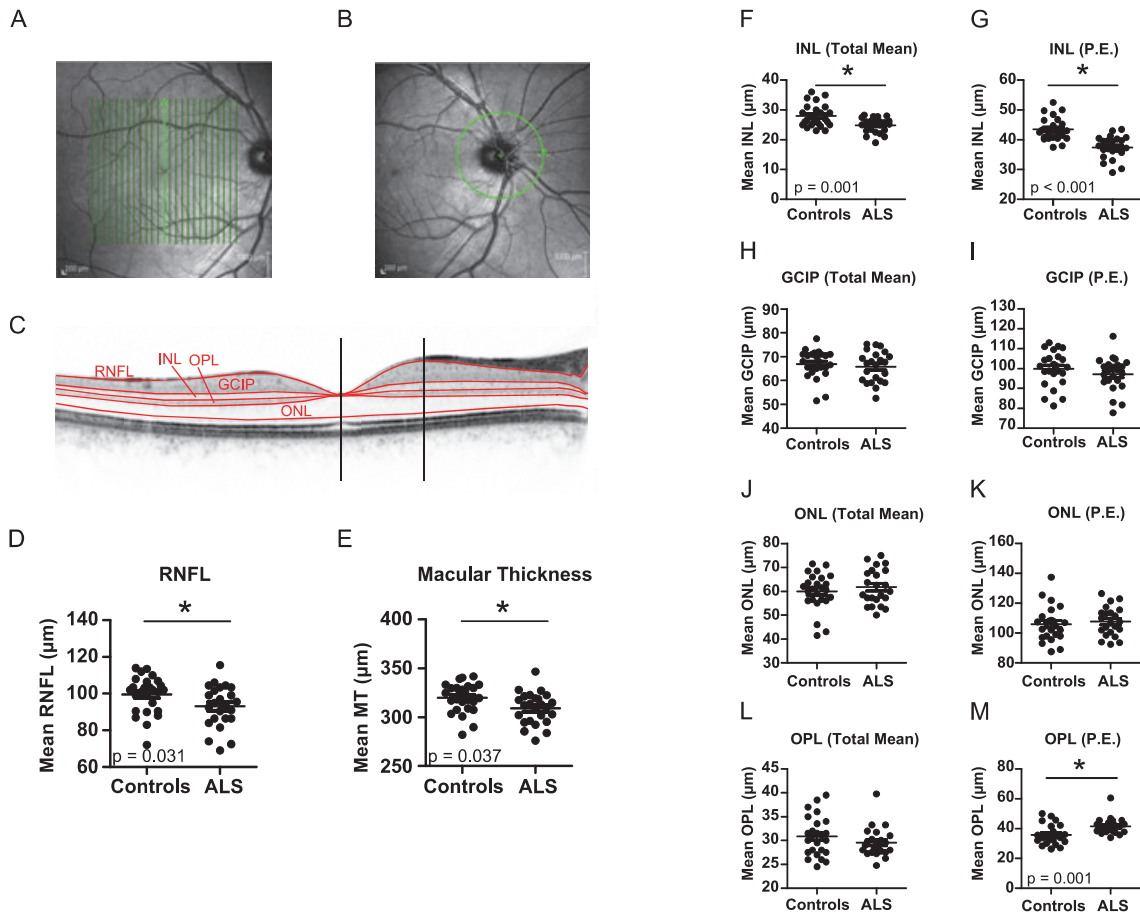


Figure 1. Optical coherence tomography (OCT) results. The macular thickness and volume were measured in consecutive vertical scans centered on the macula (A). The peripapillary RNFL was evaluated in a circular scan centered on the optic disk (B). The deeper retinal layers were manually segmented in a single horizontal foveal scan (red lines; C). The thickness of the different layers was assessed 1. as mean thickness of the entire layers, 2. by the point estimate (P.E.) method (vertical black lines). Scatter plots display the thickness of the RNFL (means ± standard deviation (M ± SD): ALS 93.2 ± 10.7 μm vs. controls 100.0 ± 10.9 μm, P = 0.031; (D)) and the total macular thickness (M ± SD: ALS 309.8 ± 17.3 μm vs. controls 318.2 ± 15.7 μm, P = 0.037; (E)) both significantly (*) reduced in ALS patients. The INL is significantly (*) reduced with both segmentation methods (mean thickness M ± SD: 24.7 ± 3.2 μm, p = 0.001; P.E. M ± SD: 37.4 ± 4.6 μm, P < 0.001) compared to controls (mean thickness M ± SD: 27.9 ± 4.3 μm; P.E. M ± SD: 43.3 ± 4.2 μm; (F+G)). No significant differences in the thickness of the mean GCIP (mean thickness, M ± SD: ALS 66.2 ± 6.6 μm vs. controls 66.5 ± 6.6 μm, P = 0.943; P.E., M ± SD: ALS 97.1 ± 8.8 μm vs. controls 100.0 ± 9.2 μm, P = 0.296; (H+I)) and the ONL (mean thickness, M ± SD: ALS 61.6 ± 7.5 μm vs. controls 60.5 ± 7.8 μm, P = 0.526; P.E., M ± SD: ALS 107.7 ± 10.6 μm vs. controls 105.9 ± 12.7 μm, P = 0.603; (J+K)) were detectable. The OPL was thicker in ALS patients when measured as P.E. (M ± SD: ALS 41.3 ± 6.0 μm vs. controls 35.5 ± 7.0 μm, P = 0.001) while the mean OPL thickness did not differ between patients and controls (M ± SD: ALS 29.5 ± 3.6 μm vs. controls 30.9 ± 4.5 μm, P = 0.161; (L+M)). Each point represents the mean of the two eyes of one patient. The mean of all patients is indicated by a horizontal bar. The P-values are indicated (GEE analysis). ALS, amyotrophic lateral sclerosis; GCIP, ganglion cell/inner plexiform layer complex; INL, inner nuclear layer; MT, macular thickness; ONL, outer nuclear layer; OPL, outer plexiform layer; P.E., point estimate; RNFL, retinal nerve fiber layer.

layers in a single high-resolution horizontal scan through the middle of the fovea (Fig. 1C). RNFL measurements and high-resolution single horizontal scans were averaged from 100 images, scans for volumetric calculations from 10 images (Automatic Real Time, ART). All scans had sufficient quality (>20 DB). Scans not fulfilling the OSCAR-IB criteria¹⁷ for retinal OCT quality assessment were excluded from the analysis.

Retinal segmentation

Manual segmentation was performed by two independent raters to assess the inter-rater reliability. Due to the low contrast between the ganglion cell layer and the inner plexiform layer both were combined and evaluated as one GCIP. To quantify the segmented layers, two different methods were employed: (1) the mean

thickness of the different entire layers was calculated using the Eye Explorer[®] software, and (2) the thickness of the deeper retinal layers was measured as point estimates (P.E.) at the thickest point nasally and temporally for all layers, except for the ONL, which was measured at the middle of the fovea as previously described (Fig. 1C).¹⁸

Statistical evaluation

Data are given as means with standard deviations (SD) and analyzed using Prism 5.0 (GraphPad, San Diego, CA) and SPSS Statistics 20 (IBM, Armonk, NY). Differences between patients and controls were tested with generalized estimation equation (GEE) models accounting for within-subject intereye correlations correcting for gender and age. No adjustment for multiple comparisons was made in light of the exploratory approach of this study. Pearson or Spearman correlation analyses were used depending on scaling and normality (Kolmogorov-Smirnov test) of the respective data. We used partial bivariate correlation analysis correcting for age and gender to analyze the association between the retinal parameters altered in ALS patients and the clinical modified Rankin Scale (mRS)¹⁹ as well as the disease duration, considering the left eyes of patients. *P*-values below 0.05 were considered significant.

Results

Reduction in RNFL, mean total macular thickness, and inner nuclear layer

The retinal nerve fiber layer (RNFL) was significantly reduced in ALS patients by 6.7% (ALS $93.2 \pm 10.7 \mu\text{m}$ vs. controls $100.0 \pm 10.9 \mu\text{m}$; $P = 0.031$ GEE; Fig. 1D). The total macular was significantly thinner in ALS as well, albeit less prominent by 2.6% (ALS $309.8 \pm 17.3 \mu\text{m}$ vs. controls $318.2 \pm 15.7 \mu\text{m}$, $P = 0.037$; Fig. 1E). Retinal segmentation revealed a significant reduction in the inner nuclear layer (INL) in ALS patients, ranging from 11.3% (mean thickness approach; $P = 0.001$) to 13.6% (P.E. approach; $P < 0.001$; Fig. 1F+G). We observed no differences in the mean retinal GCIP and the outer nuclear layer (ONL). Of note, the outer plexiform layer (OPL) was thicker in ALS patients when analyzed as point estimates ($P = 0.001$) (Fig. 1H–M).

Retinal parameters and clinical presentation

Regarding the proportion of ALS patients with OCT alterations, we applied a cutoff of two standard deviations below the mean of normal controls to define abnormal

values. We identified 3/24 (12.5%) ALS patients with abnormal RNFL ($<79.3 \mu\text{m}$), 3/24 (12.5%) cases with altered mean macular thickness ($<289.6 \mu\text{m}$), 6/24 (25%) patients with reduced INL measured as point estimates ($<35.8 \mu\text{m}$), and one patient (4%) with mean INL reduction ($<20.49 \mu\text{m}$).

Considering a possible link between retinal neurodegeneration and clinical disease characteristics, we correlated disease duration and severity with OCT parameters. Partial bivariate correlation analysis correcting for age and gender revealed no association of the modified Rankin Scale or the disease duration with the thickness of the RNFL, the INL (measured as mean or P.E.) or the total macula.

Correlation between point estimate measurement and mean whole-layer thickness

The mean thickness measurement of the complete layers calculated by the Heidelberg Eye Explorer[®] software correlated well with the P.E. approach for all layers (Pearson $P < 0.01$, Fig. 2A–D). These correlations were excellent for the GCIP (Pearson $r = 0.83$, $P < 0.0001$), the INL (Pearson $r = 0.87$, $P < 0.0001$), and the OPL (Pearson $r = 0.89$, $P < 0.0001$) and acceptable for the ONL (Pearson $r = 0.67$, $P = 0.0017$), which was the only layer measured at a single point in the foveal center by the P.E. method (Fig. 2A–D).

Inter-rater reliability of manual segmentation

To compare the reproducibility of the segmentation approaches we performed all segmentations by two independent raters and calculated the intraclass correlation coefficients (ICC) for both methods. All analyses resulted in good ($\text{ICC} \geq 0.5$) to excellent ($\text{ICC} \geq 0.9$) inter-rater reliabilities (Fig. 2E–L).

Discussion

Amyotrophic lateral sclerosis is increasingly being considered a complex neurodegenerative disease^{1,2} comprising extra-motor symptoms like fatigue, pathological laughing and crying, mild sensory symptoms, and cognitive decline,^{20–23} as well as visual deficits.^{4–6} Here we provide a morphological correlate for the latter as our data indicate retinal degeneration in ALS. Using last-generation SD-OCT methodology, we were able to detect a mild reduction in the total macular thickness, and manual segmentation revealed a unique pattern of retinal pathology: while we found a reduction in the retinal nerve fiber layer, suggesting

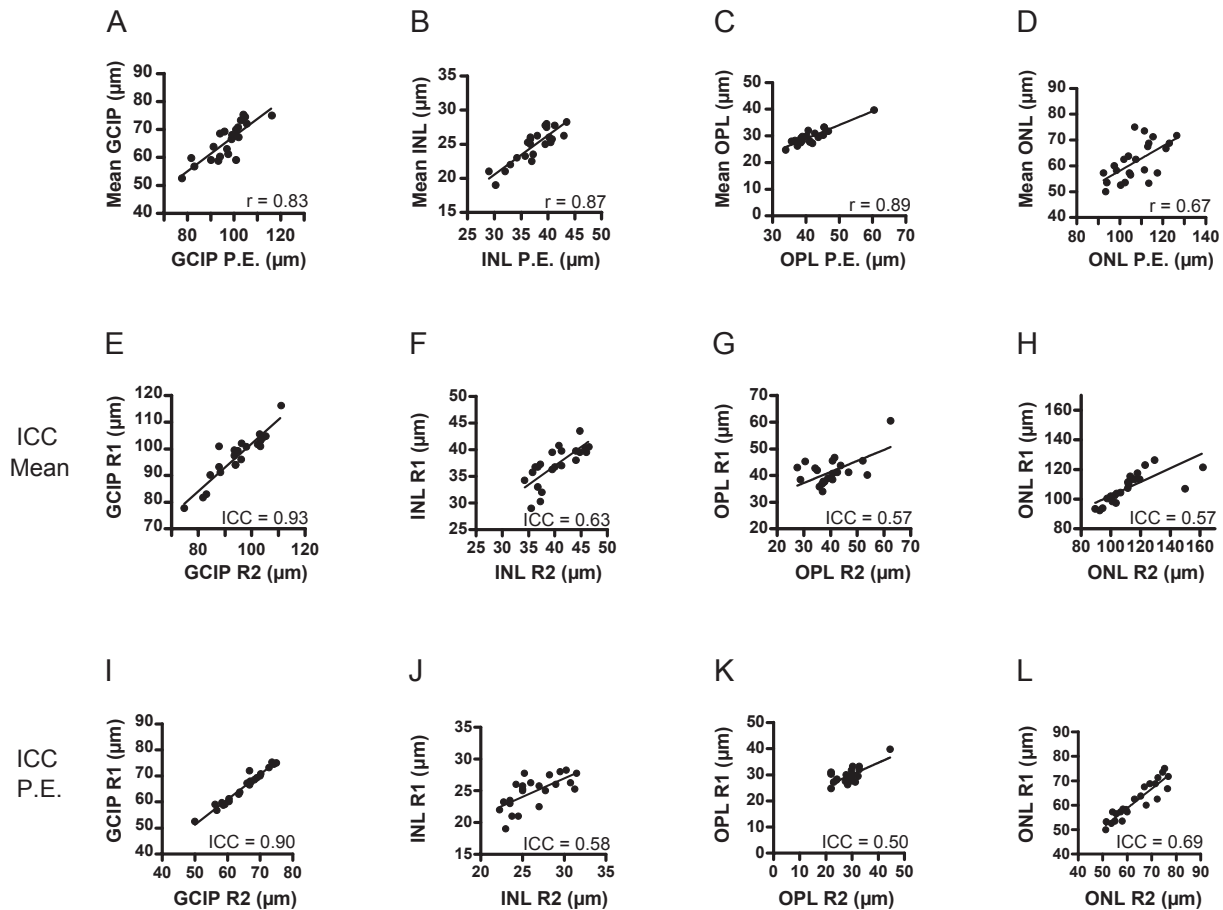


Figure 2. Correlations between the point estimate and mean entire layer segmentation methods and inter-rater reliability for both techniques. The values obtained by the point estimate (P.E.) method correlated significantly with the mean layer thickness for all layers ($P < 0.05$, Pearson correlation, Pearson r is indicated). The two segmentation methods correlated excellently ($r \geq 0.8$) for the GCIP ($r = 0.83$, $P < 0.0001$), the INL ($r = 0.87$, $P < 0.0001$) and the OPL ($r = 0.89$, $P < 0.0001$; (A–C)) and were acceptable ($r \geq 0.5$) for the ONL ($r = 0.67$, $P = 0.0017$; (D)). The values obtained by two different raters (R1 and R2) using the two segmentation methods are correlated and the intraclass correlation coefficients (ICC) are given. The GCIP measured as mean layer thickness and P.E. showed excellent inter-rater reliabilities (IRR) with ICC of ≥ 0.9 (mean layer: 0.93; (E), P.E.: 0.90; (I)). The IRR of the other layers were good with an ICC of ≥ 0.5 (INL: mean layer: 0.63; (F), P.E.: 0.58; (J)), OPL: mean layer: 0.57; (G), P.E.: 0.50; (K)), ONL: mean layer: 0.57; (H), P.E.: 0.69; (L)). Each point represents the thickness of the retinal layers of the left eye of a patient measured with the indicated methods. The diagonal lines resemble the results of linear regression analyses. GCIP, ganglion cell/inner plexiform layer complex; ICC, intraclass correlation coefficient; INL, inner nuclear layer; Mean, mean layer thickness; ONL, outer nuclear layer; OPL, outer plexiform layer; P.E., point estimate; R, rater.

axonal degeneration in ALS, and a marked thinning of the INL, the corresponding GCIP was not altered. Possibly the thinning of the RNFL is associated with degeneration of the corresponding neurons in the GCL but compensatory processes in the IPL mask the thinning of the GCL when measuring the GCIP as a single entity. The INL contains the cell bodies and nuclei of the horizontal, bipolar, and amacrine cells, specialized retinal interneurons, integrating between the light sensitive photoreceptor cells (rods and cones) with their nuclei and cell bodies located in the ONL and the ganglion cells. The synaptic portions between the nuclear cell

layers constitute the IPL and OPL. The reason for the INL reduction and the associated involvement of the RNFL in ALS remains elusive.

Distinct pathologies of the optic nerve have not been reported in ALS. This and the fact that the RNFL but not the GCIP was significantly altered in this study, render a retrograde degeneration rather improbable, even though voxel-based MRI volumetry and histopathology revealed cortex affection also in occipital regions of the brain.^{3,7} Until today it remains unclear whether alteration of the deeper retinal layers is caused by retrograde transsynaptic

degeneration as observed after optic nerve transection in animal models²⁴ or after cerebral infarction in stroke patients.²⁵ In MS, primary retinal neurodegeneration mechanisms are discussed, since atrophy of the deeper retinal layers is not necessarily linked to a previous history of optic neuritis.^{11,12} Therefore, in ALS one may assume a primary retinal process involving neuronal and consecutive axonal degeneration similar to the established mechanisms leading to upper and lower motor neuron degeneration. However, regarding the course and phenotype of retinal alterations during CNS neurodegeneration, recent studies in MS have identified a complex pattern, as an INL thickening associated with a more pronounced inflammation or a more severe disease course was observed.^{26,27} This was thought to be the result of enhanced microglial activation, partly associated with microcystic lesions within the INL. At the same time patients with long-standing primary progressive MS were reported to exhibit a significant thinning of the INL,¹² and a distinct INL/ONL thinning was observed in patients with predominantly macular thinning.¹¹ However, the latter pattern was not reproduced in a subsequent study.²⁸ Moreover, INL atrophy was detected by histopathology in 40% of investigated eyes of MS patients with a long-standing progressive disease course.²⁹ Thus, one may postulate stage-dependent processes: microglial activation during early inflammatory phases of MS may entail microcystic edema and result in transient INL thickening, followed by an INL thinning in later neurodegenerative disease stages. In our “clinically probable or definite” ALS patients¹⁶ with later disease stages (mean disease duration of 22 months) we observed a marked INL reduction. Thus, considering microglia activation as an integral part of ALS neuropathology,¹ an investigation of the time course of retinal pathology in ALS is warranted and might reveal an INL thickening in early stages as observed in MS.

Remarkably, a recent report failed to detect any retinal involvement in ALS, based on 15 patients with definite, 33 with probable, eight with laboratory supported probable and 20 with possible ALS, recruited from two centers.³⁰ The differences to this study could be explained by the heterogeneity of the patient cohorts, as the percentage of patients with definite ALS was 19.7% in the previous study, in contrast to 83.3% in our work. Furthermore, in light of recent data on the impact of gender on retinal parameters even in the absence of disease,³¹ one has to consider that healthy controls were not sex-matched in the previous study. For OCT analysis, Roth *et al.*³⁰ used an automated segmentation without manual correction, whereas we employed two different manual segmentation methods performed by two independent raters yielding an excellent correlation,

especially for the INL which we found to be thinner in ALS.

Our report has obvious limitations as confounding factors of retinal diseases in this elderly patient cohort could not finally be excluded, even though age- and sex-matched healthy controls were recruited for this study and an ophthalmologic examination by board-certified ophthalmologists was applied. Furthermore, for correlation of OCT alterations with clinical parameters, the disease-specific rating scale ALSFRS-R³² was not available for all patients, so that the modified Rankin Scale¹⁹ was used instead.

Nevertheless, our data support previously reported independent clinical and neurophysiological reports on visual disturbances in ALS and indicate a neurodegenerative process comprising the retina. Of note, the here reported pattern shows differences to retinal alterations found in other neurodegenerative diseases like parkinsonian syndromes.^{13–15} Prospective studies to evaluate the progression of retinal alterations and to assess the possible contribution of OCT to disease characterization are warranted.

Acknowledgments

We are indebted to our ALS patients, their relatives, and the healthy controls. We thank the Walter and Ilse Rose Stiftung, the “Helmholtz Alliance for Mental Health in an Ageing Society” (HelMA, HA-215), and the “Helmholtz Impuls- und Vernetzungsfonds” funded by the German “Bundesministerium für Bildung und Forschung” (BMBF) for support.

Disclosures

Marius Ringelstein received speaker honoraria from Novartis and travel reimbursement from Bayer Schering and Biogen Idec. Philipp Albrecht received research grants from Novartis, Biogen Idec, Teva, Merz Pharmaceuticals and travel/accommodations/meeting expenses by Novartis, Teva, Biogen Idec, Merz Pharmaceuticals, Ipsen, Esai and Glaxo Smith Kline. Martin Südmeyer received honoraria for lectures, travel, accommodations, and meeting expenses by Teva, Medtronic, Abbvie, Meda and Novartis. Jens Harmel received speaker honoraria from Novartis. Ann-Kristin Müller received travel reimbursement from Genzyme. Nazmiye Keser has nothing to disclose. David Finis received speaker honoraria and travel reimbursement from TearScience, Oculus and Thea-Pharma. Rainer Guthoff received speaker honoraria and travel/accommodations/meeting expenses by Novartis and Bayer Schering. Stefano Ferrea has nothing to disclose. Alfons Schnitzler has nothing to disclose. Hans-Peter Hartung received grants by the Walter and Ilse Rose Stiftung, the Eugène

Devic European Network (EU-FP7) and the German Ministry for Education and Research, received honoraria for consultancy by Bayer Health Care, Biogen Idec, Genzyme, Novartis, Teva, Sanofi Aventis, Hoffman La Roche and holds patents. Axel Methner received honoraria for consultancy from Biogen Idec and received travel/accommodations/meeting expenses from TEVA and Biogen Idec. Orhan Aktas received grants by German Research Foundation (DFG), Eugène Devic European Network (EU-FP7), German Ministry for Education and Research, Schauler Foundation, honoraria for lectures by Novartis, Bayer Schering, Teva, Biogen Idec, holds patents, and received travel/accommodations/meeting expenses by Novartis, Bayer Schering, and Merck Serono.

Authors' Contributions

Marius Ringelstein designed and conceptualized the study, collected, analyzed, and interpreted the data and drafted and revised the manuscript. Philipp Albrecht collected, analyzed, and interpreted the data, performed the statistical analysis, and drafted and revised the manuscript. Martin Südmeyer designed and conceptualized the study, recruited the patients, and drafted and revised the manuscript. Jens Harmel collected, analyzed, and interpreted the data created the Figures and drafted and revised the manuscript. Ann-Kristin Müller collected, analyzed, and interpreted the data and drafted and revised the manuscript. Nazmiye Keser collected, analyzed, and interpreted the data and drafted and revised the manuscript. David Finis designed and conceptualized the study, performed the ophthalmological examinations, and drafted and revised the manuscript. Stefano Ferrea designed and conceptualized the study, recruited the patients, and drafted and revised the manuscript. Rainer Guthoff designed and conceptualized the study, performed the ophthalmological examinations, and drafted and revised the manuscript. Alfons Schnitzler designed and conceptualized the study and drafted and revised the manuscript. Hans-Peter Hartung designed and conceptualized the study and drafted and revised the manuscript. Axel Methner designed and conceptualized the study, analyzed, and interpreted the data and drafted and revised the manuscript. Orhan Aktas designed and conceptualized the study, collected, analyzed, and interpreted the data, performed the statistical analysis, and drafted and revised the manuscript.

References

1. Kiernan MC, Vucic S, Cheah BC, et al. Amyotrophic lateral sclerosis. *Lancet* 2011;377:942–955.
2. Ludolph AC, Brettschneider J, Weishaupt JH. Amyotrophic lateral sclerosis. *Curr Opin Neurol* 2012;25:530–535.
3. Brettschneider J, Del TK, Toledo JB, et al. Stages of pTDP-43 pathology in amyotrophic lateral sclerosis. *Ann Neurol* 2013;74:20–38.
4. Sharma R, Hicks S, Berna CM, et al. Oculomotor dysfunction in amyotrophic lateral sclerosis: a comprehensive review. *Arch Neurol* 2011;68:857–861.
5. Moss HE, McCluskey L, Elman L, et al. Cross-sectional evaluation of clinical neuro-ophthalmic abnormalities in an amyotrophic lateral sclerosis population. *J Neurol Sci* 2012;314:97–101.
6. Munte TF, Troger MC, Nusser I, et al. Alteration of early components of the visual evoked potential in amyotrophic lateral sclerosis. *J Neurol* 1998;245:206–210.
7. Bede P, Bokde A, Elamin M, et al. Grey matter correlates of clinical variables in amyotrophic lateral sclerosis (ALS): a neuroimaging study of ALS motor phenotype heterogeneity and cortical focality. *J Neurol Neurosurg Psychiatry* 2013;84:766–773.
8. Drexler W, Morgner U, Ghanta RK, et al. Ultrahigh-resolution ophthalmic optical coherence tomography. *Nat Med* 2001;7:502–507.
9. Gelfand JM, Goodin DS, Boscardin WJ, et al. Retinal axonal loss begins early in the course of multiple sclerosis and is similar between progressive phenotypes. *PLoS ONE* 2012;7:e36847.
10. Walter SD, Ishikawa H, Galetta KM, et al. Ganglion cell loss in relation to visual disability in multiple sclerosis. *Ophthalmology* 2012;119:1250–1257.
11. Saidha S, Syc SB, Ibrahim MA, et al. Primary retinal pathology in multiple sclerosis as detected by optical coherence tomography. *Brain* 2011;134:518–533.
12. Albrecht P, Ringelstein M, Muller AK, et al. Degeneration of retinal layers in multiple sclerosis subtypes quantified by optical coherence tomography. *Mult Scler* 2012;18:1422–1429.
13. Albrecht P, Muller AK, Sudmeyer M, et al. Optical coherence tomography in parkinsonian syndromes. *PLoS ONE* 2012;7:e34891.
14. Albrecht P, Muller AK, Ringelstein M, et al. Retinal neurodegeneration in Wilson's disease revealed by spectral domain optical coherence tomography. *PLoS ONE* 2012;7:e49825.
15. Kesler A, Vakhapova V, Korczyn AD, et al. Retinal thickness in patients with mild cognitive impairment and Alzheimer's disease. *Clin Neurol Neurosurg* 2011;113:523–526.
16. De Carvalho M, Dengler R, Eisen A, et al. Electrodiagnostic criteria for diagnosis of ALS. *Clin Neurophysiol* 2008;119:497–503.
17. Tewarie P, Balk L, Costello F, et al. The OSCAR-IB consensus criteria for retinal OCT quality assessment. *PLoS ONE* 2012;7:e34823.
18. Seigo MA, Sotirchos ES, Newsome S, et al. In vivo assessment of retinal neuronal layers in multiple sclerosis

- with manual and automated optical coherence tomography segmentation techniques. *J Neurol* 2012;259:2119–2130.
19. van Swieten JC, Koudstaal PJ, Visser MC, et al. Interobserver agreement for the assessment of handicap in stroke patients. *Stroke* 1988;19:604–607.
 20. Abraham A, Drory VE. Fatigue in motor neuron diseases. *Neuromuscul Disord* 2012;22(Suppl 3):S198–S202.
 21. Olney NT, Goodkind MS, Lomen-Hoerth C, et al. Behaviour, physiology and experience of pathological laughing and crying in amyotrophic lateral sclerosis. *Brain* 2011;134:3458–3469.
 22. Weis J, Katona I, Muller-Newen G, et al. Small-fiber neuropathy in patients with ALS. *Neurology* 2011;76:2024–2029.
 23. Phukan J, Elamin M, Bede P, et al. The syndrome of cognitive impairment in amyotrophic lateral sclerosis: a population-based study. *J Neurol Neurosurg Psychiatry* 2012;83:102–108.
 24. Kielczewski JL, Pease ME, Quigley HA. The effect of experimental glaucoma and optic nerve transection on amacrine cells in the rat retina. *Invest Ophthalmol Vis Sci* 2005;46:3188–3196.
 25. Park HY, Park YG, Cho AH, et al. Transneuronal retrograde degeneration of the retinal ganglion cells in patients with cerebral infarction. *Ophthalmology* 2013;120:1292–1299.
 26. Saidha S, Sotirchos ES, Ibrahim MA, et al. Microcystic macular oedema, thickness of the inner nuclear layer of the retina, and disease characteristics in multiple sclerosis: a retrospective study. *Lancet Neurol* 2012;11:963–972.
 27. Kaufhold F, Zimmermann H, Schneider E, et al. Optic neuritis is associated with inner nuclear layer thickening and microcystic macular edema independently of multiple sclerosis. *PLoS ONE* 2013;8:e71145.
 28. Brandt AU, Oberwahrenbrock T, Ringelstein M, et al. Primary retinal pathology in multiple sclerosis as detected by optical coherence tomography. *Brain* 2011;134:e193.
 29. Green AJ, McQuaid S, Hauser SL, et al. Ocular pathology in multiple sclerosis: retinal atrophy and inflammation irrespective of disease duration. *Brain* 2010;133:1591–1601.
 30. Roth NM, Saidha S, Zimmermann H, et al. Optical coherence tomography does not support optic nerve involvement in amyotrophic lateral sclerosis. *Eur J Neurol* 2013;20:1170–1176.
 31. Wexler A, Sand T, Elsas TB. Macular thickness measurements in healthy Norwegian volunteers: an optical coherence tomography study. *BMC Ophthalmol* 2010;10:13.
 32. Cedarbaum JM, Stambler N, Malta E, et al. The ALSFRS-R: a revised ALS functional rating scale that incorporates assessments of respiratory function. BDNF ALS Study Group (Phase III). *J Neurol Sci* 1999;169:13–21.